

DOI: 10.4172/2472-1905.100049

# High-Intensity Focused Electromagnetic (HIFEM) Field Therapy Used for Non-Invasive Buttock Augmentation and Lifting: Feasibility Study

**Mariano Busso<sup>1\*</sup> and Radina Denkova<sup>2</sup>**<sup>1</sup>Aesthetic Dermatology, 306 Aviation Avenue Suite 2C, Coconut Grove, FL, 33133, USA<sup>2</sup>Aesthe Clinic Beauty, Sofia, BG

\* **Corresponding author:** Mariano Busso, Aesthetic Dermatology, 306 Aviation Avenue Suite 2C, Coconut Grove, FL, 33133, USA, Tel: +1 305-857-0144; E-mail: drbusso@aol.com

**Received date:** April 9, 2019; **Accepted date:** April 24, 2019; **Published date:** May 4, 2019**Citation:** Busso M, Denkova R (2019) High-Intensity Focused Electromagnetic (HIFEM) Field Therapy Used for Non-Invasive Buttock Augmentation and Lifting: Feasibility Study. J Aesthet Reconstr Surg. Vol 5 No.1:2.**Copyright:** © 2019 Busso M, et al. This is an open-access article distributed under the terms of the Creative Commons Attribution License, which permits unrestricted use, distribution, and reproduction in any medium, provided the original author and source are credited.

## Abstract

Although latest trends indicate increasing demand for aesthetic improvement of buttocks, there is currently no alternative to injectable or surgical buttock augmentation. We aimed to investigate the feasibility of the High-Intensity Focused Electromagnetic field (HIFEM) therapy for buttock shaping. 21 women received 4 HIFEM sessions (lasting 30 minutes) focused on gluteal muscles. Subjects were evaluated at baseline, after the last treatment, and at 1-month/3-month follow-ups. The evaluation comprised weight measurement, level of treatment comfort and satisfaction (Visual Analogue Scale, 0-10 range) questionnaire. Visual improvement in digital photographs was assessed by three independent evaluators using the Global Aesthetic Improvement Scale (GAIS). The average satisfaction score after the last treatment was  $7.2 \pm 1.84$  and increased at 1-month ( $7.4 \pm 1.79$ ) and 3-month ( $7.8 \pm 1.95$ ) follow-ups. The comfort level after the last treatment was  $8.3 \pm 1.9$ . Weight change was insignificant. None of the subjects reported discomfort. GAIS score for the after photos was  $1.56 \pm 0.68$  and was maintained at 1-month ( $1.51 \pm 0.65$ ) and 3-month ( $1.53 \pm 0.66$ ) follow-up. Digital photographs showed aesthetic improvement in most patients through improved shape and volume of the treated area, overall buttock lifting and reduction in muscle laxity. We suggest the device is suitable for non-invasive buttock augmentation as an alternative to surgical procedures.

**Keywords:** Field therapy; Buttock augmentation; Gluteal muscles

## Introduction

High-Intensity Focused Electromagnetic (HIFEM) field technology utilizes the principles of magnetic stimulation. It is based on application of rapidly changing magnetic fields that generate electrical currents in the underlying tissue where it depolarizes motor neurons and causes muscle contractions [1]. If the frequency of the stimulation is higher than the time needed for the muscle relaxation, the muscle is forced into

tetanic contraction which is a highly stressful condition triggering changes in the muscles as an adapting response to these conditions [2]. Published studies showed its' efficacy in increasing the muscle mass [3,4] accompanied with apoptosis [5] and consequent fat reduction [3-7]. However, all conducted studies applied the treatment on the abdomen, and the effects on other body parts have not yet been documented.

As the HIFEM technology directly stimulates muscles, it could very well be used for toning and strengthening of muscular body parts such as buttocks. By volume, gluteus maximus is one of the largest muscles in the human body, and its' stimulation could provide beneficial results for the patient. The number of buttock shaping procedures is increasing every year as people desire to augment and tone their buttocks [8]. Currently, the most popular procedures such as fat grafting, silicone implant or traditional butt lift are, however, invasive and carry a high risk of complications [8].

HIFEM technology, on the other hand, could be potentially used for noninvasive toning of buttocks as a safe alternative to current buttock shaping procedures. We hypothesize that use of the HIFEM technology on the gluteal muscles may induce hypertrophy of these muscles, as it has been seen on the muscles of the abdomen, and as such it could lead to aesthetic improvement of the buttocks by lifting the gluteal fold and firming the structure of gluteal muscles. The goal of this study is to perform an initial investigation of the feasibility, safety, and efficacy of buttock treatments by a device utilizing the HIFEM technology (EMSCULPT, BTL Industries, Boston, MA).

## Methods

The subject group was composed of 21 females, with a mean age of  $32.5 \pm 7.5$  and mean BMI of  $22.0 \pm 2.6$ . Subjects with metallic implants and any other contraindicated conditions were excluded from the study.

The treatment protocol was composed of four sessions administered during two consecutive weeks with a minimum of two-day rest between two sessions. Emsculpt device (BTL Industries, Boston MA) was used for the treatments. Subjects were lying down on their abdomen and a coil applicator

inducing magnetic fields was placed over the buttock to stimulate the left and right gluteus maximus muscles. Positioning the applicator above the inferior gluteal nerve was crucial for homogenous stimulation, the intensity was therefore initially set to 15% of the device output, and the position of the applicator was adjusted for inducing contractions of the entire gluteal area. Once the proper position of the applicator was found, the intensity was increased up to the patients' tolerance threshold and was further adjusted throughout the treatment based on the patient's feedback.

The treatment time of each side of the buttock was 30 minutes. Weight measurements and digital photographs were taken immediately after the last treatment, during 1-month follow-up and 3-month follow-up. In addition, subjects were asked to fill patient satisfaction and comfort questionnaires. Clinical efficacy was evaluated using the Global Aesthetic Improvement Scale (GAIS). It is a photograph-based instrument for grading the overall improvement by comparing the after intervention photographs to the baseline photographs (**Table 1**).

**Table 1:** The Global Aesthetic Improvement Scale.

Score	Rating	Description
3	Very much improved	An excellent corrective result
2	Much improved	Marked improvement of the appearance
1	Improved	Improvement in the appearance, better compared with the original condition
0	No change	The appearance substantially remains the same compared with the original condition
-1	Worse	The appearance has worsened compared with the baseline condition

Three independent evaluators were presented pairs of "before-after", "before-follow - up" photographs which they visually examined and graded according to the GAIS.

A visual analog scale (VAS) with a score ranging from 0 to 10 (0=absolutely dissatisfied, 10=absolutely satisfied) was used to assess the patient satisfaction with the treatments after the last treatment, and during one-month and three-month follow-ups. Patients' comfort with the treatments was assessed after the last treatment using VAS questionnaire with a score range 0-10, where 0 stands for unbearable discomfort and 10 for no discomfort. During each treatment and follow up visit patients were monitored for any side effects and adverse events.

## Ethics

All subjects received oral instructions and information after which they signed informed consent.

## Statistics

Fluctuation of the subject's weight was statistically analyzed using the paired t-test with significance level set as 5%.

## Results

All recruited subjects completed the 4 treatments with a device utilizing HIFEM technology, after treatment follow-up visits and phone call evaluation. GAIS score showed that patients significantly improved post-treatment. The patients found the treatments comfortable and showed high satisfaction which was gradually increasing.

Photo evaluation using the GAIS grading system resulted in a score of  $1.56 \pm 0.68$  when the baseline photographs were

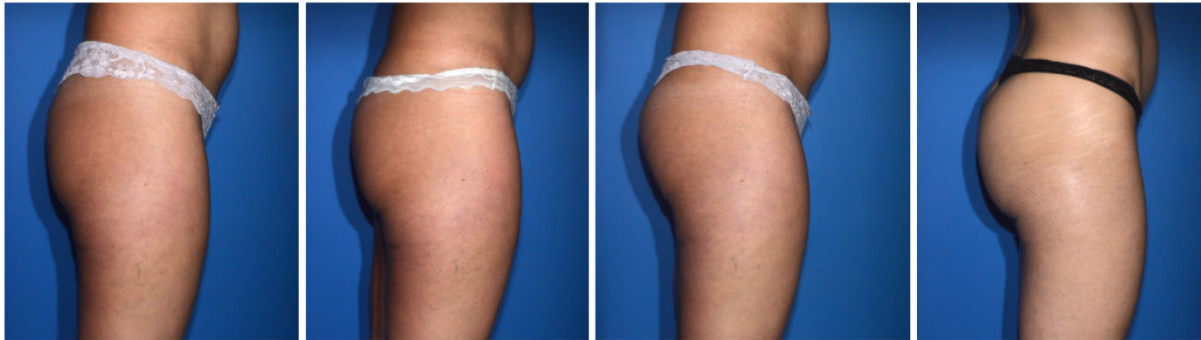compared to the ones taken immediately after the last treatment. For the photo pairs, baseline and 1-month follow-up, the average score of the three evaluators was  $1.51 \pm 0.65$ . The improvement score at three months was  $1.53 \pm 0.66$  indicating that the improvement seen immediately after the last treatment was maintained over the course of 3 months. Example of a set of patient photographs can be seen in **Figure 1**.

The figure shows mild improvement in the buttock shape and volume immediately post-treatment. The more dramatic change in comparison to baseline can be seen in the photo taken 1 month post-treatment showing lifted and more toned buttocks with significantly increased volume. The three month follow-up photo shows that the lifted buttock shape was preserved and the volume continued to increase.

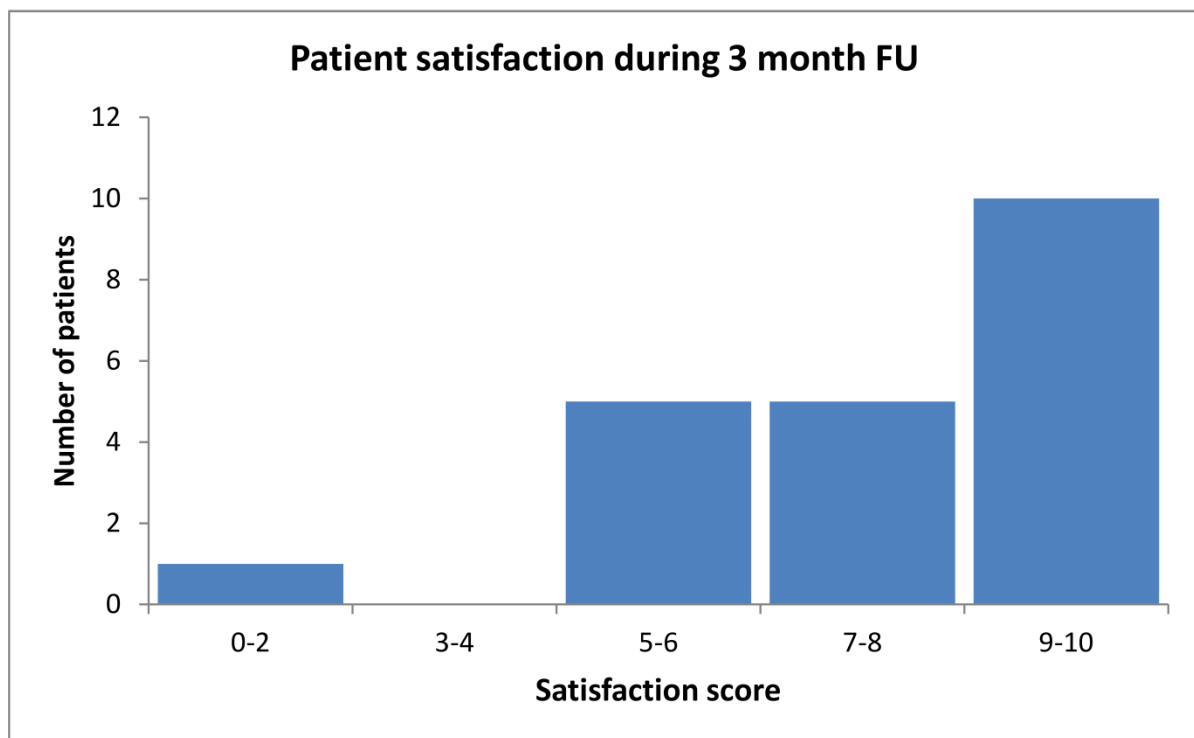
Evaluation of VAS satisfaction questionnaires resulted in high patient satisfaction with the treatment outcomes as the average VAS score was  $7.2 \pm 1.84$  after the last treatment. The satisfaction increased during the 1-month follow-up to  $7.4 \pm 1.79$  and was further enhanced to  $7.8 \pm 1.95$  during the 3-month follow-up. The histogram representing the distribution of patient satisfaction during the 3-month follow-up is displayed in **Figure 2**.

It shows that there was one dissatisfied patient (score<5), while 10 patients reported satisfaction higher than 8.

Furthermore, subjects found the treatments comfortable with VAS score of  $8.3 \pm 1.9$ . None of the patients reported discomfort during the treatments (score<5). Average weight change did not exceed 1 lb during the study and was not statistically significant ( $p>0.05$ ). Mild muscle soreness was present on the day after the treatment session in several subjects but resolved within 24 hours. No adverse events or side effects were reported.



**Figure 1:** Digital photographs of subject ID 6 taken at baseline (left), after the 4th treatment (middle left), during the one-month follow-up (middle right) and three-month follow-up (right). The photographs illustrate gradual progress in the shape of the buttocks.



**Figure 2:** Distribution of patient satisfaction score during the 3-month follow-up.

## Discussion

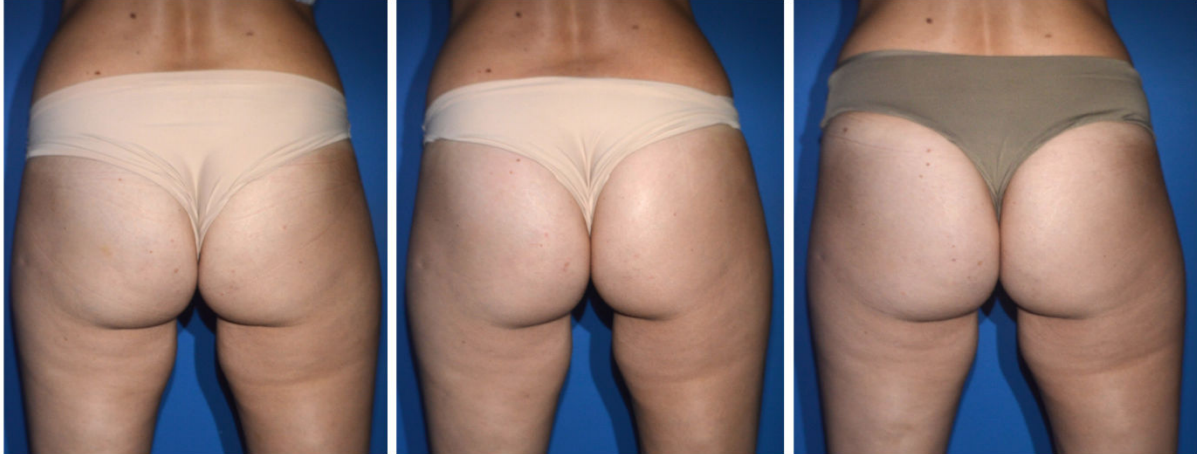The analysis of the study outcomes suggests that the HIFEM technology is feasible for aesthetic improvements of buttocks, with the treatments being safe and comfortable for the patient. The GAIS scores for all analyzed pairs of photos (“before-after” and “before-follow up”) were on the scale in between “Improved” and “Much improved,” indicating that the appearance of buttocks was significantly enhanced. The patient satisfaction continued to grow throughout the study (score = 7.2 after the last treatment, score = 7.4 during the 1 month fu) with a peak during the 3-month follow-up (score = 7.8) suggesting

that the appearance continued to improve even after 3 months since the last treatment.

The visual examination of the photographs indicates that the treatment with HIFEM technology may not induce large volumetric changes as seen with fat grafting or silicone implants, but rather induces firming effect which corrects the unpleasant sagging look into lifted and sporty appearance. A demonstrative example of this effect is displayed in **Figure 3**.

The figure shows the toning effect of the treatments, at baseline the buttock is saggy in comparison to post-treatment photos. The main difference can be seen when focusing on the gluteal fold and intergluteal cleft, the buttock at post-treatment

photos is lifted, firmer and gives the impression of fuller look. In addition, a slight volumetric enhancement can be seen in the 3-month photograph.



**Figure 3:** Photographs of a 25-year-old female (Subject ID 7) taken at baseline (left), after the 4th treatment (middle) and after 3 months (right).

Photographs demonstrate the firming effect of the treatments as the gluteal fold is lifted in the after intervention photograph. Previous abdominal studies [3,4,7] documented reduction in subcutaneous fat thickness after treatments by HIFEM technology device. This effect, however, may be an undesirable outcome of the buttock treatments for most of the patients, as fat deposits on buttocks may contribute to its fuller look. We did not measure the fat deposits, but it has been documented before, that the fat tissue of buttocks is much less metabolically active when compared to fat tissue of the abdomen. It can, therefore, be assumed that the fat layer of buttocks is not significantly affected during the treatments [9,10].

We thus link the observed aesthetic improvement solely to the HIFEM effect on muscles as previous studies [3,4] report approximately 16% increase in muscle thickness. Since the muscle laxity plays crucial role in the sagging look of buttock the correction of muscle laxity is the key for improving the buttock appearance and creating the desired sporty look. The HIFEM technology allows treatment of muscle laxity through induction of supramaximal muscle contractions.

Even though the used evaluation methodologies give promising results of the HIFEM technology for the buttock shaping, a quantitative evaluation is missing. Future studies should bring a quantitative and more objective evaluation of the buttock treatments e.g., MRI measurements of muscle thickness, MRI muscle volume assessment or 3D photograph volumetric assessment. Extended protocol with an increased number of treatments including long-term monitoring of the patient should also be considered for future research.

## Conclusion

The HIFEM technology showed its capability in improving aesthetic improvement of buttocks which was demonstrated by

the positive GAIS ratings given by three independent evaluators and high patient satisfaction. Marked improvements observed in the digital photographs suggest the HIFEM treatments for buttocks as a suitable alternative to current procedures. Further research including quantitative assessment is necessary.

## Acknowledgments

None. No funding to declare.

## Conflict of Interest

Mariano Busso MD is a speaker for BTL. Radina Denkova MD has no relevant conflicts to declare.

## References

1. Barker AT (1991) An introduction to the basic principles of magnetic nerve stimulation. *J Clin Neurophysiol Off Publ Am Electroencephalogr Soc* 8: 26-37.
2. Jones DA, Bigland-Ritchie B, Edwards RHT (1979) Excitation frequency and muscle fatigue: Mechanical responses during voluntary and stimulated contractions. *Exp Neurol* 64: 401-13.
3. Kinney BM, Lozanova P (2018) High intensity focused electromagnetic therapy evaluated by magnetic resonance imaging: Safety and efficacy study of a dual tissue effect based non-invasive abdominal body shaping. *Lasers Surg Med*.
4. Kent DE, Jacob CI (2018) Computed tomography (CT) based evidence of simultaneous changes in human adipose and muscle tissues following a high intensity focused electro-magnetic (HIFEM) application: a new method for non-invasive body sculpting.
5. Weiss R, Bernardy J (2018) Induction of fat apoptosis by a non-thermal device: safety and mechanism of action of non-invasive HIFEM technology evaluated in a histological porcine model. Present Annu Meet Am Soc Lasers Surg Med.

6. Jacob CI, Paskova K (2018) Safety and efficacy of a novel highintensity focused electromagnetic technology device for noninvasive abdominal body shaping. *J Cosmet Dermatol*.
7. Katz BE, Bard RL, Goldfarb R, Shiloh A, Kenolova D (2018) Changes in subcutaneous abdominal fat thickness following high-intensity focused electro-magnetic HIFEM field treatments: a multi-center ultrasound study. In Dallas TX, USA: *Lasers Surg Med P*: 360-61.
8. The American Society for Aesthetic Plastic Surgery (2016) *Procedural Statistics*.
9. Brouwers B, Hesselink MKC, Schrauwen P, Schrauwen-Hinderling VB (2016) Effects of exercise training on intrahepatic lipid content in humans. *Diabetologia* 59: 2068-79.
10. Bjørndal B, Burri L, Staalesen V, Skorve J, Berge RK (2011) Different adipose depots: their role in the development of metabolic syndrome and mitochondrial response to hypolipidemic agents. *J Obes* 490650.