

ISSN: 1545 9616

JOURNAL OF DRUGS IN DERMATOLOGY

JDD

---

DRUGS • DEVICES • METHODS

---

HUMAN ADIPOCYTE APOPTOSIS  
IMMEDIATELY FOLLOWING  
HIGH FREQUENCY FOCUSED  
FIELD RADIO FREQUENCY:  
CASE STUDY

*David McDaniel MD and Paula Lozanova MD*

J Drugs in Dermatol. 2015;14(6):622-623.

# Human Adipocyte Apoptosis Immediately Following High Frequency Focused Field Radio Frequency: Case Study

David McDaniel MD<sup>a</sup> and Paula Lozanova MD<sup>b</sup>

<sup>a</sup>McDaniel Institute of Anti-Aging Research, Virginia Beach, VA

<sup>b</sup>Department of Dermatology and Venerology, Medical University, Sofia, Bulgaria

## ABSTRACT

**Background:** A previously published study used a radio frequency (RF) focused field device (Vanquish, BTL Industries Ltd., Framingham, MA) to reduce porcine abdominal fat. The purpose of this case study was to reproduce the veterinary study on human subjects. The primary objective was measurement of apoptotic index before and after treatment with the RF device. As a second outcome demonstrating selective heating and safety, superficial skin temperature and temperature 1 and 2 cm into the subcutaneous tissue were measured.

**Methods and Measurements:** Two healthy female subjects underwent abdominal skin and fat biopsies at baseline and after one treatment with a similar focused field high frequency RF device capable of 200 watts for 45 minutes. Biopsies were performed 1 hour post-treatment and were analyzed using the TUNEL method. Infrared imaging of the skin surface temperature was measured in both subjects. Thermocouple measurements at 1 and 2 cm were performed during the treatment cycle on a single subject.

**Results:** Histologic apoptotic index (pre and 1 hour post) showed an average increase of 487% (6.5 to 31.7). Thermal imaging demonstrated an average surface temperature of 31.6°C pre-treatment and 39.2°C post-treatment. The 1 cm depth thermocouple showed an initial temperature of 40°C and reached a maximum of 45°C 15 minutes into the treatment. It remained stable at 45°C for the remaining 30 minutes treatment time. No adverse events were noted.

**Conclusion:** RF treatment induces an increase in apoptotic index in adipocytes 1 hour post-RF treatment. This is accompanied by a peak temperature of 45°C in the fat layer. Skin surface temperatures remain substantially lower than fat temperatures.

*J Drugs Dermatol.* 2015;14(6):622-623.

## INTRODUCTION

Apoptosis or programmed cell death is a central mechanism for maintaining homeostasis. This natural process of cell removal enables the body to rid itself of selected cells safely and effectively.<sup>1</sup> The potential benefits of induced apoptosis, specifically to the abdominal region, extends beyond aesthetics as it may help reduce metabolic complications in overweight patients.<sup>2</sup>

By inducing apoptosis instead of necrosis in patients undergoing radio frequency (RF) therapy, less harm and side effects with greater patient safety can be achieved. A previously published porcine model study<sup>3</sup> showed significant increase in apoptotic index after treatment with a focused field RF device (Vanquish, BTL Industries Ltd.). The main objective of this study is to reproduce the results of the veterinary study and measure changes in apoptotic index after a single RF treatment in human subjects. In histological material, apoptotic index is used as a measure of the extent of apoptosis. Most often it is defined as a percentage of apoptotic cells and bodies per all cells.<sup>4</sup>

The use of thermal imaging during heat inducing treatments provides a reliable means in which to monitor skin and subcutaneous tissue temperature.<sup>5</sup> To evaluate the selectivity of adipose tissue heating and safety of the device, superficial skin temperature and temperature at 1 and 2 cm depth were measured.

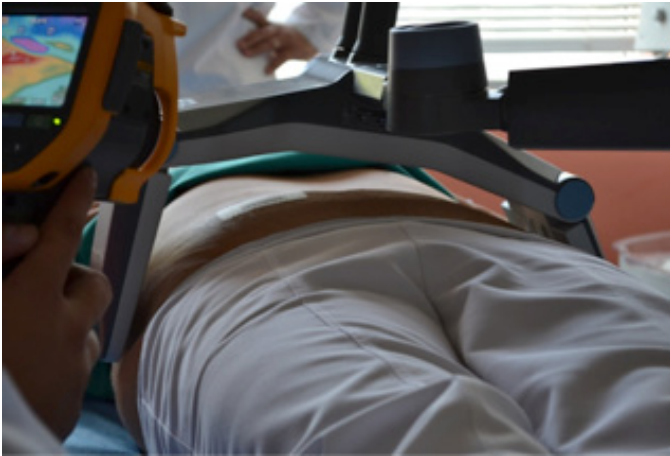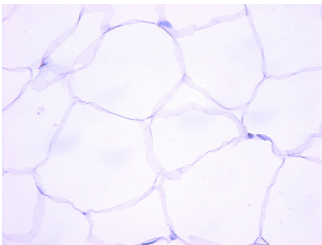
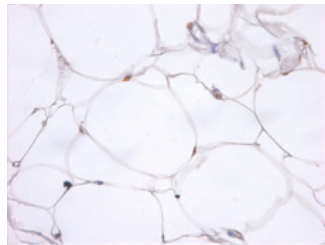
## METHODS AND MEASUREMENTS

Participants of this IRB-approved case study were two healthy female subjects that met all inclusion/exclusion criteria, which included visible excess fat to the abdomen (BMI's 27 and 29). To evaluate changes in apoptotic activity in the adipose tissue, 5 mm tissue biopsies were taken approximately 2 weeks prior to treatment and 1 hour post treatment with the RF device. The treatment protocol included one 45-minute treatment with the device placed over the abdomen (Figure 1). Power was set at 200 Watts and titrated down based on patients' report of heat tolerance. During the treatment superficial skin temperature was measured using the FLIR e60 infrared camera system (FLIR Systems, Inc., Wilsonville, OR). A thermocouple was used to measure the subcutaneous tissue at 1 and 2 cm depth.

The biopsies were fixed and processed with 10 unstained slices for TUNEL (terminal deoxynucleotidyl transferase UTP nick end labeling) assay for evaluation of apoptotic activity in the adipose tissue. Apoptotic nuclei were imaged using Leica DM-IRB microscope and Nikon DS-Fi2 camera and related image analysis software. As an outcome, apoptotic indexes were measured and values from samples before and after treatment were compared.

## RESULTS

Comparison of samples taken before and after treatment evaluated by TUNEL assays showed significant increase in

**FIGURE 1.** Subject and device positioning before the treatment.**FIGURE 2.** TUNEL stained tissue sections. Brown stained nuclei indicate apoptotic cells.**a) Baseline****b) 1 hour after treatment**

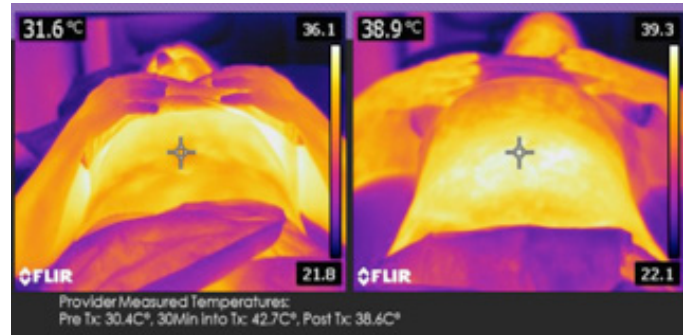
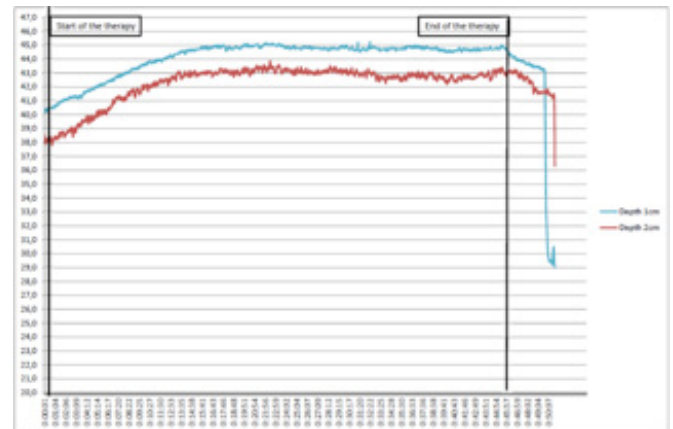
apoptotic index. Average value increased 487% from baseline to 1 hour post treatment, 6.5 to 31.7, respectively. T-test was applied to evaluate results. They were considered statistically strong with  $P < 0.001$ . For evidence of apoptotic nuclei by TUNEL staining see Figure 2.

Surface skin temperature measurements by FLIR infrared camera showed similar characteristics by both subjects and the peak surface temperature remained below 43° C (Figure 3).

Thermocouple placed in 1 cm depth showed initial temperature 40° C that 15 minutes after beginning of the therapy reached 45° C where it remained stable for the rest of the treatment. Analogous progression was measured by the 2 cm depth thermocouple. It started at 38° C and rapidly grew to 43° C within 15 minutes and remained stable until the end of the treatment (Figure 4). No adverse events were reported. Treatment side effects included transient mild erythema.

## CONCLUSION

Results of this case study suggest that deep tissue heating by a focused field RF device has strong influence on increasing the number of adipocytes undergoing apoptosis. Thermo-

**FIGURE 3.** Skin surface temperatures pre and immediately post-treatment.**FIGURE 4.** Temperature course during the treatment session.

couple measurements demonstrated a rise in temperature in the target layer. Skin temperature measured by infrared camera remained notably cooler.

## DISCLOSURES

Dr. McDaniel serves a consultant to BTL Industries.

## REFERENCES

- Herold C, Rennekampff H, Engeli S. (n.d.). Apoptotic pathways in adipose tissue. *Apoptosis*. 911-916. Retrieved March 30, 2015.
- Zhang Y, Huang C. Targeting adipocyte apoptosis: A novel strategy for obesity therapy; *Biochem Biophys Res Commun*. 2012; 417(1):1-4.
- Weiss R, Weiss M, Beasley K, Vrba J, Bernardy J. Operator independent focused high frequency ISM band for fat reduction: Porcine model; *Lasers Surg Med*. 2013; 45(4): 235–239.
- Soini Y, Pääkkö P, Lehto V (n.d.). Histopathological evaluation of apoptosis in cancer. *Am J Pathol*. 153(4):1041-1053.
- Key DJ. Preliminary Demonstration using localized skin temperature elevation as observed with thermal imaging as an indicator of fat-specific absorption during focus-field radiofrequency therapy; *J Drugs Dermatol*. 2014;13(7):864-866.

## AUTHOR CORRESPONDENCE

**Paula Lozanova MD**

E-mail:..... paula\_lozanova@yahoo.com

